

Clinical Review

 **Ultrasound-Guided Peripheral Nerve Stimulation for Shoulder Pain: Anatomic Review and Assessment of the Current Clinical Evidence**

Anthony Mazzola, MD¹, and David Spinner, DO²

From: ¹Department of Pain Medicine, the University of Texas MD Anderson Cancer Center, Houston, TX; ²Department of Rehabilitation and Human Performance, Icahn School of Medicine, Mount Sinai Health System, New York, NY

Address Correspondence:
Anthony Mazzola, MD
Department of Pain Medicine,
the University of Texas MD
Anderson Cancer Center,
Houston, TX
E-mail: anthonyjmazzola@gmail.com

Disclaimer: There was no external funding in the preparation of this manuscript. Conflict of interest: Dr. Mazzola has no conflicts of interest to report. None of the authors of the manuscript received any remuneration. Further, the authors have not received any reimbursement or honorarium in any other manner. Dr. Spinner reports his role as advisor for Bioness, Sprint Therapeutics, and Nalu Medical.

Manuscript received: 01-18-2020
Revised manuscript received: 03-07-2020
Accepted for publication: 04-08-2020

Free full manuscript:
www.painphysicianjournal.com

Background: The shoulder region is a common area for pain. The shoulder has the largest range of motion and the most complex mechanical anatomy. The shoulder girdle and related tendons allow for numerous painful disorders to occur. Also, given the overall use of the shoulder, arthritic deformities are all too common. Finally, pain from more complex states such as poststroke shoulder pain and status post total shoulder arthroplasty pain have always been a difficult diagnosis to treat with effectiveness. The innervation to the shoulder predominantly comes from the suprascapular and axillary nerves. Both nerves relatively follow an expected anatomic course and whereby they can be targeted with ultrasound or fluoroscopy. Recently, there has been an increase in evidence that suggests peripheral nerve stimulation can make a difference in these patients with shoulder pain.

Objectives: To provide a basic overview of peripheral nerve stimulator placement targeting the axillary and suprascapular nerves. Furthermore, to demonstrate the suggested implantation and current evidence of peripheral nerve stimulation for the treatment of shoulder pain.

Study Design: Anatomic clinical review.

Methods: A comprehensive review was performed regarding the available literature through targeting articles reporting on the use of peripheral nerve stimulation to treat pain of the shoulder region.

Results: We compiled and discuss the current evidence available in treating shoulder pain utilizing peripheral stimulation. The strongest evidence currently is for peripheral nerve stimulation targeting either the axillary or suprascapular nerve, as well as placement targeting the motor points of the deltoid. The most common treated pathology is poststroke shoulder pain.

Limitations: Peripheral nerve stimulation has been trialed and is promising for several shoulder pain pathologies; however, there remains a need for large-scale, randomized, placebo-controlled clinical trials to further evaluate the efficacy of most treatments. Much of the current data relies on case reports without randomization or placebo controls.

Conclusions: Overall there is fair to moderate evidence for peripheral nerve stimulation to treat shoulder pain in hemiplegic poststroke patients. There is limited evidence when treating other shoulder pain etiologies. Utilizing ultrasound or fluoroscopic guidance, the procedure has proven to be safe allowing proper placement of the electrodes near the target nerves. Considering the high prevalence of shoulder pain from degenerative conditions and overuse, future studies are undoubtedly warranted to evaluate whether peripheral nerve stimulation can modify our treatment algorithm for management of these conditions.

Key words: Shoulder pain, suprascapular nerve, axillary nerve, ultrasonography, peripheral nerve stimulation, post stroke shoulder, osteoarthritis, rotator cuff, hemiplegic shoulder pain, adhesive capsulitis

Pain Physician 2020; 23:E461-E474

Shoulder pain is one of the top sources of musculoskeletal pain (1). The prevalence of shoulder pain ranges from 20% to 33% among the general population. Several studies seem to demonstrate an increasing trend in the reporting of shoulder pain, as well as an increasing amount of leave time taken from work secondary to shoulder pain. Shoulder pain is more frequent in women, and the overall prevalence increases with age. Although approximately 50% of new shoulder pain diagnoses resolve in 8 to 12 weeks, as many as 40% of all cases persist for longer than 1 year with a high rate of chronicity that severely impacts the patient's quality of life (2). Common shoulder pathologies include osteoarthritis, joint instability, adhesive capsulitis, rotator cuff injury, labrum tears, and neuropathic conditions (3).

Many shoulder diagnoses improve with a combination of treatments including physical therapy, medications, and directed interventions around the shoulder. Different interventions may include steroids, regenerative medicine, or viscosupplementation. There are a range of more severe shoulder pathologies that can be either neuropathic or nociceptive in origin that cause significant pain and impact life. Some of these pathologies include severe glenohumeral arthritis, status post shoulder replacement, or poststroke shoulder pain.

Many of these more painful shoulder pathologies greatly affect the patient's activities of daily living and are simply too painful or complex for physical therapy to "fix." Our common interventional options do provide relief but are often short lived. Nerve blocks around the shoulder have been shown to provide short-term relief (4,5).

Peripheral nerve stimulation was originally introduced in 1967 by Wall and Sweet (6) with the report of a patient experiencing pain relief from electrical stimulation. Later in 1999, Weiner and Reed (7) demonstrated the feasibility of percutaneous lead placement rather than the previous method requiring surgical placement. It is a well-documented hypothesis that applying electrical current to a peripheral nerve can affect the firing of that nerve and thereby modulate the pain. Advances in peripheral nerve stimulation technology along with ultrasound guidance has enabled a long-term treatment modality. Fluoroscopy and nerve stimulation techniques are viable tools to aid in device placement. Ultrasound allows for direct visualization of the nerves (suprascapular and axillary), as well as surrounding vasculature, soft tissue, and adjacent bony

landmarks (8). Technological advances have created small, thin electrical leads that can be placed percutaneously, can be used for short- or long-term duration, and have significantly less infection and migration concerns. Deer et al (9) in 2016 demonstrated peripheral nerve stimulation to have an excellent safety profile, with none of the 75 patients who received peripheral stimulation experiencing any serious or unanticipated device-related adverse reaction. Publications regarding overall peripheral nerve stimulation have been published (10), as well as innovative approaches to and applications for shoulder pathologies (11,12).

Sonoanatomy and Peripheral Nerve Stimulator Placement

Suprascapular Nerve

The suprascapular nerve innervates the glenohumeral and acromioclavicular joints while supplying motor innervation to the supraspinatus and infraspinatus muscles (Fig. 1). It originates from C5 and C6, forms part of the upper trunk of the brachial plexus, and descends inferiorly under the omohyoid muscle before it takes a turn posteriorly toward the suprascapular notch (Fig. 2). The nerve typically lies below the suprascapular ligament, whereas the artery may lie above. Nerve fibers branch off along its course as it then descends further through the spinoglenoid notch (Fig. 3). The nerve can be targeted for interventions anywhere along its course from the brachial plexus to the supra- or infraspinatus fossa. The most common location for targeting the nerve is at the suprascapular notch.

The transducer is placed in a coronal plane over the supraspinatus muscle. A linear probe can be used for smaller shoulders, whereas a curved transducer should be utilized for larger shoulders. The posterior part of the suprascapular fossa and suprascapular spine should be visualized. Care should be taken to avoid targeting anteriorly as the needle can inadvertently enter the thoracic cavity. Once the suprascapular notch is identified, the suprascapular artery can be seen above the transverse suprascapular ligament, and the suprascapular nerve below (Fig. 2). The needle is entered from a medial to lateral approach as the acromion lies laterally and does not allow for needle entry. An in-plane approach allows for needle visualization and targeting adjacent to the nerve (13).

Axillary Nerve

The axillary nerve innervates the posterior gle-

nohumeral joint and superior lateral portion of the arm while supplying motor innervation to the deltoid and teres minor muscles (Fig. 1). It originates from C5 and C6, forms part of the posterior cord of the brachial plexus, and descends inferiorly to the quadrangular space. The nerve then branches further as it traverses around the humerus at the inferior margin of the teres minor (14). The nerve can be targeted for interventions anywhere along its course from the brachial plexus to the posterior humerus. The most common location for targeting the nerve regarding peripheral nerve stimulation is at the posterior humerus.

The transducer is placed in a sagittal plane over the humeral head and neck. A linear probe can be used for smaller shoulders, whereas a curved transducer should be utilized for larger shoulders. The infraspinatus is seen in cross-section at the cranial portion, and the teres minor seen caudally (Fig. 4). The axillary nerve and circumflex artery are visualized at the inferior border of the teres minor (Fig. 5). Doppler imaging can be used to help identify vasculature (Fig. 6). The needle can enter from a caudal to cranial approach or a lateral to medial or a medial to lateral approach. Both in-plane and out-of-plane approaches have been described.

In 2018, Gofeld and Agur (11) published a proof of concept anatomy study demonstrating the implantation of a peripheral nerve stimulator targeting the axillary and suprascapular nerves. In this anatomic study, a step-by-step ultrasound-guided implantation technique was designed, and the procedure was completed targeting both the axillary and suprascapular nerves on cadaveric specimens. After dissection, the implanted devices were found adjacent to the 2 target nerves within 0.5 to 1.0 cm distance.




Fig. 1. Anatomy of posterior shoulder.




Fig. 2. Ultrasound imaging identifying the suprascapular nerve and the suprascapular artery at the location of the suprascapular notch.

METHODS

Literature on Peripheral Nerve Stimulation for Shoulder Pain

We utilized a search including “peripheral nerve stimulation” and




Fig. 3. *Ultrasound identifying the suprascapular artery at the location of the spinoglenoid notch.*




Fig. 4. *Ultrasound placed in sagittal plane over the humeral head and neck. Identify the infraspinatus, teres minor, and the posterior circumflex humeral artery adjacent to the axillary nerve.*

“shoulder pain.” Articles investigating peripheral nerve stimulation for various nerves, predominantly the axillary and suprascapular nerves, were included for reference. Articles that involved peripheral nerve stimulator implantation targeting the shoulder muscles themselves, predominantly the deltoid muscle, were also included to complete a comprehensive review of the literature. The search was performed with PubMed. The details of each included study are summarized (Table 1).

RESULTS

Hemiplegic Shoulder Pain

Hemiplegic poststroke shoulder pain proves to be the earliest and most widely studied application of peripheral nerve stimulation at the shoulder. Starting in 2001, Yu et al (15) investigated the feasibility of percutaneous intramuscular neuromuscular electric stimulation for treating shoulder subluxation and pain in patients with chronic hemiplegia. Later in 2004, Yu et al (16) published a multisite, randomized clinical trial investigating intramuscular electrical stimulation in stroke survivors to treat poststroke shoulder pain. This study included 61 chronic stroke survivors with shoulder pain randomized to a 6-week course of intramuscular electrical stimulation 6 hours per day ($n = 32$) versus a hemisling ($n = 29$) instructed to be used whenever the affected arm was unsupported. For the treatment group, percutaneous, intramuscular electrodes (helical configuration wound from Teflon-insulated, multistranded, type 316L stainless steel wires, developed at Case Western Reserve University) were implanted into the posterior deltoid, middle deltoid, supraspinatus, and trapezius muscles of the hemiplegic shoulder.

Of note, the patients selected each had shoulder subluxation and electrical stimulation intensity was adjusted to provide optimal joint reduction by palpation without discomfort and remained constant during the 6-week treatment phase. In 2005, Chae et al (17) published the 12-month post-treatment data for the earlier mentioned multicenter, single-blinded, randomized clinical trial. The electrical stimulation group exhibited a significantly higher success rate defined as at least a 2-point reduction in pain intensity scored from 0 to 10 compared with the controls (63% vs. 21%; $P = 0.001$). Post hoc analysis of 12-month intent-to-treat data using the more stringent 4-point reduction criterion yielded a much larger difference between the peripheral nerve stimulation group and the control group (68.8% vs. 27.6%; $P = 0.001$). Additionally in 2007, Chae et al (18) described a secondary analysis of the earlier mentioned studies and concluded that electrical stimulation was significantly effective in reducing poststroke shoulder pain in those with less than 77 weeks of stroke onset. However, those with time from stroke onset greater than 77 weeks showed no difference when compared with control.

In 2010, Yu et al (19) reported on the first poststroke patient treated with electrical stimulation delivered via a fully implanted microstimulator containing a rechargeable internal battery. The 58-year-old patient suffered from a stroke causing right hemiparesis 59 months before implant, and shoulder pain was present for 42 months. Patient was diagnosed with both subluxation and capsulitis of the shoulder. The microstimulator (Dakmed Peripheral Nerve Stimulator Model 750; Dakmed Inc., Buffalo, NY) was implanted near the axillary nerve within the quadrilateral space. The


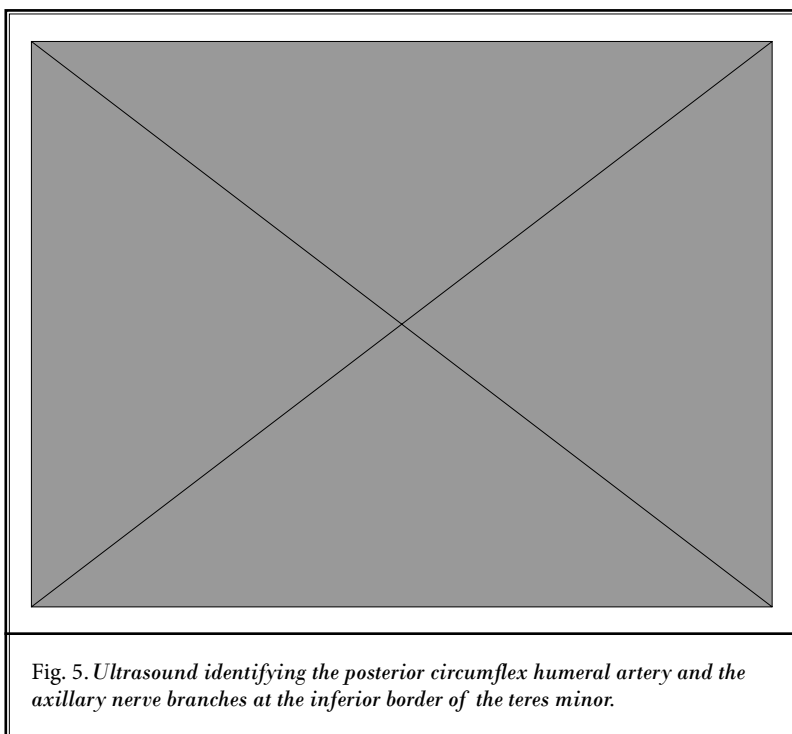


Table 1. Summary of the Studies Reviewed on Peripheral Nerve Stimulation for Treatment of Shoulder Pain

Author, Year	Design	Patients	Number	Mean age (yr)	Target(s)	Treatment(s)	Outcome(s)	Adverse Events
Chae et al, 2005 (17) 12 month follow-up data to Yu et al, 2004 (16)	RCT	Persistent hemiplegic shoulder pain post stroke with shoulder subluxation	PNS: 32 M + F Sling: 29 M + F	PNS: 60 Sling: 58	Supra-spinatus, posterior deltoid, middle deltoid, upper trapezius.	PNS: 4 percutaneous intramuscular electrodes (helical, multistranded, type 316L stainless steel wires, Case Western Reserve University) implanted and stimulus intensity adjusted to provide optimal joint reduction by palpation without discomfort for entire 6-wk of treatment period. Sling: Control subjects were instructed to wear a cuff-type hemising whenever the upper limb was unsupported	The PNS group had a significantly higher success rate defined as ≥ 2 point reduction in pain intensity score (0-10) compared to the controls (63% vs 21%, $p=0.001$). Post hoc analysis of 12-mo intent-to-treat data using the more stringent 4-point reduction criterion yielded a much larger difference between PNS and control group (68.8% vs 27.6%, $P = 0.001$).	No serious device-related adverse events. Temporary granuloma formation occurred for 5 electrodes in 2 total subjects.
Yu et al, 2010 (19)	Case report	Persistent hemiplegic shoulder pain post stroke	1 M	58.0	Axillary nerve	The microstimulator (Dakmed™ Peripheral Nerve Stimulator Model 750, Buffalo, NY) was implanted near the axillary nerve within the quadrilateral space with stimulation for 6 hrs per day for 12 wks.	Pain decreased from 8/10 to 4/10 after a 12 wk treatment period and decreased further to 3/10 at 3 month follow-up. Passive range of motion and motor function also improved.	No serious device-related adverse events.
Chae et al, 2013 (20)	Case series	Persistent hemiplegic shoulder pain post stroke	4 M 4 F	50.3	Axillary nerve (deltoid muscle)	A single percutaneous intramuscular lead (Rehablicare® NT2000, Empi, Inc, St. Paul, MN) in the hemiparetic deltoid muscle treated 6-hrs a day for 3 wks. All leads were removed at end of treatment.	On average participants exhibited 70% reduction in the Brief Pain Inventory Question 3 and all satisfied the success criterion of ≥ 2 point reduction in above score.	All leads remained infection free and were removed intact without serious complications. Mild erythema (n=4), small granuloma (n=3, and blister (n=1) all resolved.
Nguyen et al 2015 (21)	Case report	Persistent hemiplegic shoulder pain post stroke	1 M	77.0	Axillary nerve	Percutaneous electrode implanted near the terminal branches of the axillary nerve connected to the IPG, single-channel stimulator, (MICROPULSE™, NDI Medical, Cleveland, OH) delivered stimulation 6 hrs daily.	75% pain relief during 3 wk trial. Post-implantation, he was pain free after 3 wks. However, at 7 wks device was turned off due to unrelated medical condition and pain returned. After treatment resumed, patient was pain free through 9 months; at 12 months pain score was 1/10.	No serious device-related adverse events.
Wilson et al, 2014 (22)	RCT	Persistent hemiplegic shoulder pain in stroke survivors	PNS: 7 M F PT: 5 M F	PNS: 54.0 PT: 58.3	Axillary nerve (deltoid muscle)	PNS: Percutaneous intramuscular single electrode placed to an external stimulator (SMARTPATCH® PNS System, SPR Therapeutics, LLC, Cleveland, Ohio) for 6 hrs of stimulation a day for 3 wks. PT: 8 hrs of outpatient PT over 4 wks and home program.	Significantly greater reductions in pain for the PNS group (65.3% at end of 3 wks of treatment and 60% at 12 wks after) compared to the usual care controls. Both groups had significant improvements in pain interference and physical related quality of life.	Required re-implantation after dislodgement of electrode (n=1). Pruritis at the electrode or bandage site (n=6). Pain after implantation which improved (n=2).

Table 1. Summary of the Studies Reviewed on Peripheral Nerve Stimulation for Treatment of Shoulder Pain

Author, Year	Design	Patients	Number	Mean age (yr)	Target(s)	Treatment(s)	Outcome(s)	Adverse Events
Wilson et al. 2018, (24)	Case series	Persistent hemiplegic shoulder pain in stroke survivors	Trial: 13 M 15 F Implant: 3 M 2 F	Trial: 54.0 Implant: 62.7	Axillary nerve (deltoid muscle)	Trial: Percutaneous intramuscular electrode (Rehabicare® NT2000, Empi, Inc., St. Paul, MN or SPRINT™ PNS SYSTEM, SPR Therapeutics, LLC, Cleveland, Ohio) connected to external pulse stimulator for 6 hrs for 3 wks. Implant: IPG was a single-channel stimulator (MICROPULSE™; NDI Medical, Cleveland, OH).	Trial: 57.1% had a successful percutaneous trial defined as having at least 2-point reduction during active stimulation at end of trial. 21.4% of the patients had subsequent return of pain. Implant: Those patients with return of pain that underwent implant (n=5) had an overall reduction in pain by 69.2% at 6 months, 84.6% at 12 months, and 69.2% at 24 months.	No serious events related to device. Granulomas /erythema/pruritus at lead exit (n=8). Erythema/ pruritus/rash/ abrasion (n=1). Painful ketoid stim (n=5). Painful ketoid (n=1). Requiring re-implantation (n=1 non-functioning; n=1 suboptimal placement). Tenderness (n=1).
Author, Year	Design	Patients	Number	Mean age (yr)	Target(s)	Treatment	Outcome	Adverse Events
Mehech et al, 2018 (25)	Case report	Persistent shoulder pain post spinal cord injury	1 M	45.0	Axillary nerve (deltoid muscle)	Percutaneous electrode implanted at axillary nerve motor point and connected to stimulator (SPRINT™ (formerly SMARTPATCH™) PNS SYSTEM, SPR Therapeutics, LLC, Cleveland, OH, USA) for 6 hours of stimulation per day for 3 wks.	At 1 wk after treatment patient reported his worst pain had decreased by 44%, however this returned to baseline over the 12 wk follow-up period. Pain interference decreased and remained below baseline for the 12 wks follow-up.	There was a subjective increase in the subject's arm tone that resolved.
Oswald et al, 2019 (10) *Note: data reported from total of all nerves implanted (n=39)	Case series	Persistent post stroke shoulder pain (n=6); Unknown (n=13)	19 M + F 46%* M 54%* F	61.0*M 59.0* F	Axillary (n=18); or supra-scapular nerve (n=1)	Percutaneous electrical leads (StimRouter™; Bioness, Valencia, CA) connected to an external pulse stimulator used for on average 6.2 days per wk for axillary nerve and 4.5 days per wk for suprascapular nerve.	Pain relief by 70.1% (8.0/10 to 2.4/10) post implant on axillary nerve. Pain relief by 66.7% (9.0/10 to 3.0/10) post implant on suprascapular nerve.	Adverse events were not measured.
Wilson et al, 2014 (26)	Case series	Intractable subacromial impingement syndrome	4 M 6 F	52.2	Axillary nerve (deltoid muscle)	Percutaneous intramuscular electrode (Smartpatch™, SPR Therapeutics, Cleveland, OH) connected to an external pulse stimulator used for 6 hrs a day for 3 wks.	Overall 36.6% reduction in pain at 3 wks and 48.8% at 16 wks. A 2 point or 30% reduction in pain at 3 wks was met for 6 out of 10 participants.	70% developed a granuloma at the electrode site that resolved by 16 weeks.

Table 1. Summary of the Studies Reviewed on Peripheral Nerve Stimulation for Treatment of Shoulder Pain

Author, Year	Design	Patients	Number	Mean age (yr)	Target(s)	Treatment	Outcome	Adverse Events
Elahi et al, 2014 (27)	Case report	Refractory shoulder pain secondary to adhesive capsulitis	1 F	39.0	Suprascapular nerve	An 8 contact lead (Medtronic compact 1X8 low impedance 3778-75, Minneapolis, MN).	At 3 month follow-up pain was rated a 1-2/10 and she no longer had pain at rest.	No serious device-related adverse events.
Erkan et al, 2016 (28)	Case report	Chronic intractable shoulder pain (cervical myelopathy)	1 M	52.0	Suprascapular nerve	A single quad lead (Pisces Quad compact™, Medtronic, Minneapolis, MN) implanted with a permanent IPG (Prime Advanced™, Medtronic).	Pain-free for 9 months post implant with no need for pain medication and improved quality of life.	No serious device-related adverse events.
Ifeld et al, 2019 (29)	Proof of concept study	Postoperative rotator cuff repair	14 M 2 F	55.0	Suprascapular nerve (n=2), brachial plexus roots or trunks (n=14)	Percutaneous electrode (MicroLead™, SPR Therapeutics, Cleveland, Ohio, n=14) or (OnePass™, SPR Therapeutics, n=2). Postoperatively subjects received 5 mins of either stim or sham randomized with 5 mins crossover. After continuous stim delivered until lead removal at postoperative days 14 through 29.	No significant improvement of pain scores with lead targeting the suprascapular nerve (n=2). However, with leads targeting the brachial plexus (n=14), average pain scores decreased by 1 point, dynamic pain scores decreased by 3 or more, and opioid requirements averaged < 1 tablet of 5mg oxycodone daily with active stimulation.	Lead partially unwound from its helical coil and stopped functioning (n=1). Unwanted muscle contraction (n=1). Accidental lead removal (n=1).
Mansfield et al, 2019 (30)	Case report	Primary shoulder osteoarthritis	1 M	91.0	Axillary nerve	First with a temporary percutaneous single-lead (SPRINT, SPR, Cleveland, OH, USA) for 60 days. After return of pain, permanent electrical lead (StimRouter™; Bioness, Valencia, CA) connected to an external pulse stimulator.	Reported a 70% pain relief during the 60 day period with the temporary stimulator. After the device was removed, pain returned within several weeks. After permanent implant patient endorsed >70% pain relief for a study period of 8 months.	No adverse events reported.
Mansfield et al, 2020 (31)	Case series	Chronic shoulder pain (multiple musculoskeletal diagnoses)	8 M + F	no data	Axillary nerve	Percutaneous placed single lead implant (StimRouter™; Bioness, Valencia, CA) connected to an external pulse transmitter to deliver stimulation.	7 of the 8 patients were responders with ≥50% pain reduction post treatment with average follow-up varying from 44 to 733 days (average 445 days) Overall pain reduction was 67% (8.14/10 to 2.7/10).	No associated complications reported.

Abbreviations: M, male; F, female; ROM, range of motion; hrs, hours; wks, weeks; PT, physical therapy; mins, minutes

patient's shoulder pain decreased from 8/10 to 4/10 after a 12-week treatment period, and decreased further to 3/10 at 3-month follow-up. Passive range of motion and motor function also improved.

In 2013, Chae et al (20) published a case series investigating the feasibility of a percutaneous single-lead (Rehabicare NT2000; Empi, Inc., St. Paul, MN) approach used to stimulate the axillary nerve via motor points in the middle and posterior deltoids for 3 weeks to treat chronic hemiplegic poststroke shoulder pain. Eight out of 8 patients were responsive to treatment with at least a 2-point pain reduction in pain intensity scores at the end of the 3 weeks of treatment. On average, there was a 70% pain reduction at end of treatment, 61% pain reduction at 4 weeks posttreatment, and 63% pain reduction at 12 weeks posttreatment. At the end of 12 weeks, 6 of the 8 patients maintained a reduction in pain. The authors compare these findings to those of their previous investigation (16), which utilized a 4-lead system and concludes this single-lead approach has similar efficacy compared with the 4-lead system that targeted the middle deltoid, posterior deltoid, supraspinatus, and trapezius muscles each individually. Furthermore, the authors propose that intramuscular nerve therapy may be useful for nonstroke patients, stating that the reductions seen in pain were likely not as previously proposed and mediated by purely the reduction of glenohumeral subluxation. The authors therefore suggest that peripheral nerve stimulation may be helpful to treat other diagnoses of shoulder pain.

Similar to the earlier described poststroke shoulder pain treatments, in 2015, Nguyen et al (21) demonstrated the feasibility of a single-lead, fully implantable peripheral nerve stimulation system for refractory hemiplegic shoulder pain. The patient was a 77-year-old man who developed poststroke hemiplegic shoulder pain shortly after his stroke, which occurred 10.8 years prior to enrollment. The patient underwent a 3-week sham period and a 3-week stimulation period with an external stimulator (Rehabicare NT2000; Empi, Inc.). He experienced 37.5% pain reduction during the sham period, and an additional 37.5% pain reduction during active stimulation. After the successful stimulation trial, an implantable pulse generator (IPG), single-channel (Micropulse; NDI Medical, Cleveland, OH) was implanted. By the end of the third week of stimulation the patient was pain free. However, the patient later suffered a myocardial infarction that was concluded to be unrelated to the study device. During this time, the

stimulator was inactive, and his pain returned. After reinitiation of treatment with active stimulation, the patient's pain once again improved through the study period of 12 months.

In 2014, Wilson et al (22) investigated a randomized controlled trial comparing peripheral nerve stimulation to the usual care for pain relief of hemiplegic shoulder pain. Patients were randomized to receive 3-week treatment of single-lead peripheral nerve stimulation ($n = 13$) versus the usual care ($n = 12$). Those in the peripheral nerve stimulation group received a single percutaneous electrode targeting the motor points of the middle and posterior deltoid muscle and were attached to an external stimulator (Rehabicare NT2000, Empi, Inc.).{AU: Please confirm edits in the previous sentence} Patients were prescribed 6 hours of stimulation per day for 3 weeks. Those in the usual care group received 8 hours of outpatient physical therapy over a 4-week period coupled with a home exercise program. There were significantly greater reductions in pain for the peripheral nerve stimulation group compared with the usual care controls at both 6 and 12 weeks posttreatment. Both groups had significant improvements in pain interference and physically related quality of life. In 2017, Wilson et al (23) further published on the secondary outcomes including the effect of peripheral nerve stimulation on shoulder biomechanics. Although there were significant improvements in biomechanical outcome measures, including max isometric shoulder abduction strength, pain-free external rotation range of motion, and Fugl-Meyer motor assessment, there were no significant differences between the groups.

In 2018, Wilson et al (24) reported a multisite case series studying fully implantable peripheral nerve stimulation to treat hemiplegic shoulder pain. Some 16 of the 28 total patients had a successful 3-week blinded sham introductory period with 2 external stimulators (Rehabicare NT2000; Empi, Inc. or Sprint PNS System; SPR Therapeutics, LLC, Cleveland, OH). After the 3 weeks of stimulation, 10 of these 16 patients had no return of pain. Six of the successful trials had return of pain and 5 of these patients (1 patient withdrew) were subsequently implanted with a pulse generator (Micropulse; NDI Medical) and an electrode placed to stimulate the axillary nerve motor points of the affected shoulder. There were significant reductions of pain by 69.2%, 84.6%, and 69.2% at 6 months, 12 months, and 24 months, respectively. The authors also demonstrated significant reductions in shoulder-related disability and pain interference, while also demonstrating improvements in shoulder range of motion.

In 2018, Mehech et al (25) published a case report detailing a 45-year-old patient with spinal cord injury successfully treated with percutaneous peripheral nerve stimulation of the axillary nerve with electrode targeting the midpoint between the 2 motor points of the middle and posterior deltoids. After 1 week, the stimulator (Sprint, formerly Smartpatch, SPR Therapeutics, LLC) was connected to the lead and patient received 6 hours of stimulation per day for 3 weeks. There was a subjective increase in the patient's arm tone that resolved. At 1 week after treatment, patient reported his worst pain had decreased by 44%, however, this returned to baseline over the 12-week follow-up period. Pain interference decreased and remained below baseline for the 12-week follow-up.

In 2019, Oswald et al (10) reported on a case series of outcomes of 39 patients implanted with peripheral nerve stimulation (StimRouter system, Bioness, Valencia, CA) for mononeuropathies of various diagnoses, predominantly poststroke shoulder pain. Overall 78% of patients noticed an improvement in their pain, and there was a 71% reduction in pain scores with the average score of 8 improving to 2 postimplant. The axillary nerve was targeted in 18 patients primarily for poststroke shoulder pain (n = 6), and the average change in pain was 70.1% (from 8.0/10 to 2.4/10). The suprascapular nerve was targeted in 1 patient of unknown diagnosis with 66.7% reduction in pain from 9.0/10 to 3.0/10. There was also a marked improvement in activity.

Subacromial Impingement Syndrome

In 2014, Wilson et al (26) published a case series investigating the effect of peripheral nerve stimulation for chronic pain in subacromial impingement syndrome. A total of 10 patients with at least 6 months of intractable shoulder pain who failed both subacromial corticosteroid injection and physical therapy, were implanted with a percutaneous intramuscular electrode (Smartpatch; SPR Therapeutics, LLC) to stimulate the terminal branches of the axillary nerve to the middle and posterior deltoids. Patients were treated 6 hours a day for 3 weeks. There were significant reductions in pain by 36.6% at the end of the 3 weeks of treatment, and by 48.8% at week 16. The authors also demonstrated significant reductions in shoulder-related disability and pain interference, while also reporting improvements in shoulder range of motion and quality of life.

Adhesive Capsulitis

In 2014, Elahi and Reddy (27) presented a 39-year-

old woman with a complex shoulder pathology history including 7 prior surgeries with continued refractory chronic pain and limited mobility of her shoulder joint secondary to adhesive shoulder capsulitis. Patient underwent a suprascapular nerve block, which improved pain, as well as a successful stimulation trial. She subsequently underwent a permanent implantation of a suprascapular nerve stimulator (compact 1X8 low impedance 3778-75; Medtronic, Minneapolis, MN) with improved pain and shoulder range of motion in all planes at the 3-month follow-up period. The authors propose that a nerve block may help select patients who may respond to peripheral stimulation.

Chronic Intractable Shoulder Pain (C5/C6 Cervical Spondylotic Myelopathy)

In 2016, Kurt et al (28) reported a 52-year-old woman with chronic intractable shoulder pain believed to be related to her cervical spondylotic myelopathy as evidenced at C5 and C6. After improvement in pain with a peripheral suprascapular nerve block with bupivacaine and cryoblockade, the patient underwent a successful trial of neurostimulation with single quad lead (Pisces Quad compact; Medtronic) targeting the suprascapular nerve for 2 weeks. She was subsequently implanted with a permanent IPG (Prime Advanced; Medtronic) and experienced no pain during the 9-month follow-up period. Of note, the authors chose to stimulate the more distal branches of the suprascapular nerve that run into the infraspinatus muscle.

Postoperative Analgesia Following Rotator Cuff Repair

In 2019, Ilfeld et al (29) investigated the use of ultrasound-guided percutaneous peripheral nerve stimulation targeting the suprascapular nerve and brachial plexus for postoperative analgesia following ambulatory rotator cuff repair in 16 patients. This proof of concept study suggests the feasibility of placing peripheral nerve stimulation leads targeting the brachial plexus, although this modality may not provide as potent analgesia as local anesthetic-based peripheral nerve blocks. In this study, the first 2 leads (MicroLead; SPR Therapeutics, LLC) implanted at the suprascapular notch did not appear to provide analgesia (n = 2), and thus subsequent leads (n = 14) were inserted through the middle scalene muscle and placed to target either the brachial plexus roots or trunks. For the last 2 patients a multicomponent implantation system (OnePass; SPR Therapeutics, LLC) was used. Postoperatively pa-

Table 2. *Qualified modified approach to grading of evidence.*

Level I	Strong	2 or more relevant high quality RCTs for effectiveness, or 4 or more relevant high quality observational studies or large case series for assessment of preventive measures, adverse, consequences, and effectiveness of other measures.
Level II	Moderate	At least 1 relevant high quality RCT or multiple relevant moderate or low quality RCTs, or at least 2 high quality relevant observational studies or large case series for assessment of preventive measures, adverse consequences, and effectiveness of other measures.
Level III	Fair	At least 1 relevant high quality nonrandomized trial or observational study with multiple moderate or low quality observation studies, or at least one high quality relevant observation study or large case series for assessment of preventative measures, adverse consequences, effectiveness of other measures.
Level IV	Limited	Multiple moderate or low quality relevant observational studies, or moderate quality observation studies or large case series for assessment of preventative measures, adverse consequences, and effectiveness of other measures.
Level V	Consensus based	Opinion or consensus of a large group of clinicians for effectiveness as well as to assess preventive measures, adverse consequences, effectiveness of other measures, or single case reports.

Table 3. *Peripheral nerve stimulation evidence for shoulder pain based on studies reviewed.*

Diagnosis (Etiology of Shoulder Pain)	Axillary Nerve	Suprascapular Nerve	Intramuscular Implantation (Deltoid)	Brachial Plexus Roots or Trunks
Hemiplegic Post Stroke	IV ^(19, 21, 10)	x	II-III ^(17*, 20, 22, 24)	x
Hemiplegic Post Spinal Cord Injury	x	x	V ⁽²⁵⁾	x
Subacromial Impingement	x	x	IV ⁽²⁶⁾	x
Adhesive Capsulitis	x	V ⁽²⁷⁾	x	x
C5/C6 Cervical Spondylotic Myelopathy	x	V ⁽²⁸⁾	x	x
Postoperative Rotator Cuff Repair	x	x	x	IV ⁽²⁹⁾
Primary Osteoarthritis	V ⁽³⁰⁾	x	x	x
Other Chronic Musculoskeletal	IV ⁽³¹⁾	x	x	x

*4 individual leads implanted into supraspinatus, posterior deltoid, middle deltoid, and upper trapezius

tients received 5 minutes of either stimulation or sham randomized with 5 minutes crossover period. Afterward, continuous stimulation was delivered until lead removal occurred at postoperative days 14 through 28. The authors conclude that peripheral nerve stimulation implanted within 1 week of surgery may provide analgesia and decrease opioid requirements in the days following rotator cuff repair, and therefore warrants further randomized clinical trials.

Primary Shoulder Osteoarthritis

In 2020, Mansfield and Desai (30) published a case report describing the use of peripheral nerve stimulation for primary osteoarthritis. This patient was a 91-year-old man with advanced end-stage osteoarthritis who was not a candidate for surgical management. Secondary to patient preference for a temporary device, the axillary nerve was implanted with a 60-day single-lead peripheral nerve stimulation implant (Sprint, SPR Therapeutics, LLC). The patient reported a greater than 70% shoulder pain reduction that was sustained throughout

the therapy. On removal of the temporary lead, the pain returned to preprocedure severity within several weeks. The patient was then implanted with a permanent single-lead implant (Bioness) along the course of the axillary nerve within the quadrangular space. The stimulation parameters included an alternating cycle of sensory and motor stimulation. The patient once again began to experience a greater than 70% pain reduction of the symptomatic shoulder through the study period of 8 months. The authors conclude that peripheral nerve stimulation may be effective for the treatment of shoulder arthritis and should be considered in cases in which surgical management is not an option.

Chronic Shoulder Pain of Different Musculoskeletal Diagnoses

In 2020, Mansfield and Desai (31) further published a retrospective case series investigating the use of peripheral nerve stimulation (StimRouter system; Bioness) on the axillary nerve to treat 8 patients with varying diagnoses of chronic shoulder pain. The pa-

tients had greater than 6 months of pain secondary to either subacromial impingement syndrome, rotator cuff pathology, glenohumeral joint arthritis, acromioclavicular joint arthritis, adhesive capsulitis, or biceps tendinopathy. Patients with poststroke shoulder pain were excluded. Seven of the 8 patients were responders with pain reduction greater than 50%, and there was an overall 67% decrease in pain scores (8.14/10 to 2.71/10). Of note, all 5 patients who were previously prescribed opioids to treat their shoulder pain reported a decrease in opioid use after peripheral nerve stimulator implantation with an average decrease of 88%. The authors conclude this retrospective case series proves level IV evidence supporting the use of axillary peripheral nerve stimulation therapy for the management of chronic shoulder pain.

DISCUSSION

Through our literature search, we found the majority of studies investigating peripheral nerve stimulation for the management of shoulder pain were either case series or case reports. When reviewing the available literature, it is crucial to define the overall level of evidence a study provides before the research conclusions can be adopted to clinical practice. Manchikanti et al (32) has developed an interventional specific pain management instrument used in assessing the methodologic quality of trials (Table 2). Traditionally, randomized controlled trials are generally considered to be superior evidence than studies without randomization and without controls. The lowest levels of evidence are obtained from observational-based clinical experience or reports of expert committees. This qualified modified approach to grading of evidence allows us to put the totality of evidence into perspective (Table 3). {AU: Please add Methods and Results headings in the text where appropriate}

The greatest evidence available in support for peripheral nerve stimulation of the shoulder is for treating hemiplegic stroke pain. This evidence includes a total of 2 randomized controlled trials. The first randomized controlled trial by Chae et al (17) concludes that peripheral nerve stimulation targeting the supraspinatus, posterior deltoid, middle deltoid, and upper trapezius had a statistically significant pain improvement in poststroke patients with both subluxation and shoulder pain when compared with the control group that used a hemisling. Later, a secondary analysis confirmed that electrical stimulation was significantly effective in reducing poststroke shoulder pain in those with less

than 77 weeks of stroke onset. However, those with time from stroke onset greater than 77 weeks showed no difference when compared with the control group (18). This highlights the possible importance of patient selection prior to intervention and supports earlier intervention may improve outcomes.

The second randomized controlled trial investigating peripheral nerve stimulation for hemiplegic shoulder pain was published by Wilson et al (22) in 2014, and also demonstrates a significantly greater reduction in pain for the peripheral nerve stimulation group when compared with the control group that received the usual standard of care, which included physical therapy. The authors conclude that 3 weeks of electrical stimulation treatment delivered through a single percutaneous lead targeting the deltoid muscle proves to significantly reduce pain in the studied hemiplegic stroke population. Although both these randomized controlled studies did compare to the usual treatment of either hemisling or physical therapy, respectively, the actual implantation and use of the peripheral nerve stimulation was not blinded to the patient, and thus the outcomes are unable to correct for any such placebo effect. Furthermore, both of these studies were relatively small populations that received the treatment intervention with only 32 and 13 patients, respectively.

In addition, regarding the Wilson et al (22) trial, some patients received physical therapy along with the peripheral nerve stimulation. The authors suggest that their intention-to-treat analysis provides confidence that a difference in pain reduction between peripheral nerve stimulation and usual care does exist, even though the confidence interval was large due to imprecision in the estimate of the differences between the groups due to variability in the data, the sample size, and missing data. Overall, these 2 randomized controlled trials along with the other published cases provide fair to moderate, level III to II, evidence for peripheral nerve stimulation for the treatment of hemiplegic poststroke shoulder pain.

Regarding the other diagnoses of shoulder there is overall limited quality of evidence. A proof of concept study by Ilfeld et al (29) attempted to provide a randomized, sham-controlled, crossover design investigating peripheral nerve stimulation for postoperative analgesia following ambulatory rotator cuff repair. These patients differ from the usual peripheral nerve stimulation patient population, which includes the chronic pain patient. Furthermore, the authors conclude that the 5-minute treatment group sham and crossover de-

sign provided little interpretable data. First, they used only 5 minutes of sham to minimize any potential time without adequate pain control. However, these 5 minutes were not likely long enough to make claims on the effectiveness of the active stimulation, as other studies suggest up to 1 hour may be needed to reach full effect. Second, the patients who received stimulation for the first 5 minutes were not allowed for an adequate washout phase, and thus the carryover effect of the peripheral nerve stimulation could affect the analgesia through the sham period.

Similarly, the other reviewed case series and reports lack comparative groups to show whether peripheral nerve stimulation is indeed better than placebo or the usual care interventions. Although the best quality data suggests fair to moderate evidence in favor of peripheral nerve stimulation for treatment of hemiplegic shoulder pain, regarding multiple other diagnoses, given this limited data, the exact magnitude of peripheral nerve stimulation efficacy is difficult to be completely determined.

Peripheral nerve stimulation is feasible for the management of shoulder pain. With the use of ultrasound guidance, the nerves can be located precisely, and the electrodes are deployed safely at the most effective locations for peripheral nerve stimulation. Neurovascular structures are readily identified thus enhancing the safety when placing stimulators in their vicinity. There were no significant adverse events in the published literature reviewed, and there are no current reports of significant neurovascular compromise with newer peripheral nerve stimulation devices. The axillary and suprascapular nerves are the primary targets for peripheral nerve stimulation of the shoulder, as well as intramuscular deltoid placement. There are reports

successfully utilizing simultaneous dual implantation and after stimulation of these nerves (12).

CONCLUSIONS

The present review examines peripheral nerve stimulation feasibility for the management of painful shoulder pathology. Overall, there is fair to moderate evidence for peripheral nerve stimulation to treat shoulder pain in hemiplegic stroke patients. Regarding other diagnoses, there are only few published case reports and series providing consensus based to limited quality evidence at this time. {AU: Please clarify, "providing consensus based to limited quality evidence at this time "}Utilizing ultrasound or fluoroscopic guidance, the procedure has proven to be safe, allowing proper placement of the electrodes near the target nerves or muscles. Considering the high prevalence of shoulder pain from degenerative conditions and overuse, future studies are undoubtedly warranted to evaluate whether peripheral nerve stimulation can modify our treatment algorithm for management of these conditions.

Acknowledgments

The authors thank the editorial board of Pain Physician for review and criticism in improving the manuscript.

Author contributions: Drs. Mazzola and Spinner had full access to all the data in the study and take responsibility for the integrity of the data and the accuracy of the data analyses. Drs. Mazzola and Spinner managed the literature searches and summaries of previous related work and wrote and edited the manuscript and provided final approval of the manuscript.

REFERENCES

1. Cadogan A, Laslett M, Hing WA, McNair PJ, Coates MH. A prospective study of shoulder pain in primary care: Prevalence of imaged pathology and response to guided diagnostic blocks. *Musculoskelet Disord* 2011; 12:119.
2. McBeth J, Jones K. Epidemiology of chronic musculoskeletal pain. *Best Pract Res Clin Rheumatol* 2007; 21:403-425.
3. Burbank KM, Stevenson JH, Czarnecki GR, Dorfman J. Chronic shoulder pain: Part I. Evaluation and diagnosis. *Am Fam Physician* 2008; 77:453-460.
4. Harmon D, Hearty C. Ultrasound-guided suprascapular nerve block technique. *Pain Physician* 2007; 10:743-746.
5. Shanahan EM, Ahern M, Smith M, Wetherall M, Bresnihan B, FitzGerald O. Suprascapular nerve block (using bupivacaine and methylprednisolone acetate) in chronic shoulder pain. *Ann Rheum Dis* 2003; 62:400-406.
6. Wall PD, Sweet WH. Temporary abolition of pain in man. *Science* 1967; 155:108-109.
7. Weiner R, Reed KL. Peripheral neurostimulation for control of intractable occipital neuralgia. *Neuromodulation* 1999; 2:217-221.
8. Spinner DA, Kirschner JS, Herrera JE (eds). *Atlas of Ultrasound Guided Musculoskeletal Injections*. New York, Springer, 2014.
9. Deer T, Pope J, Benyamin R, et al. Prospective, multicenter, randomized, double-blinded, partial crossover study to assess the safety and efficacy of the novel neuromodulation system in the treatment of patients with chronic pain of peripheral nerve origin. *Neuromodulation* 2016; 19:91-100.

10. Oswald J, Shahi V, Chakravarthy KV. Prospective case series on the use of peripheral nerve stimulation for focal mononeuropathy treatment. *Pain Manage* 2019; 9:551-558.
11. Gofeld M, Agur A. Peripheral nerve stimulation for chronic shoulder pain: A proof of concept anatomy study. *Neuromodulation* 2018; 21:284-289.
12. Sulindro AD, Spinner D, Gofeld M. Novel lead placement for suprascapular nerve peripheral nerve stimulation. North American Neuromodulation Society Meeting, January 11-14, 2018, Las Vegas, NV, USA. Poster Presentation.
13. Laumonerie P, Lapègue F, Chantalat E, Sans N, Mansat P, Faruch M. Description and ultrasound targeting of the origin of the suprascapular nerve. *Clin Anat* 2017; 30:747-752.
14. Leechavengvongs S, Teerawutthichakit T, Witoonchart K, et al. Surgical anatomy of the axillary nerve branches to the deltoid muscle. *Clin Anat* 2015; 28:118-122.
15. Yu DT, Chae J, Walker ME, et al. Percutaneous intramuscular neuromuscular electric stimulation for the treatment of shoulder subluxation and pain in patients with chronic hemiplegia: A pilot study. *Arch Phys Med Rehabil* 2001; 82:20-25.
16. Yu DT, Chae J, Walker ME, et al. Intramuscular neuromuscular electric stimulation for poststroke shoulder pain: A multicenter randomized clinical trial. *Arch Phys Med Rehabil* 2004; 85:695-704.
17. Chae J, Yu DT, Walker ME, et al. Intramuscular electrical stimulation for hemiplegic shoulder pain: A 12-month follow-up of a multiple-center, randomized clinical trial. *Am J Phys Med Rehabil* 2005; 84:832-842.
18. Chae J, Ng A, Yu DT, et al. Intramuscular electrical stimulation for shoulder pain in hemiplegia: Does time from stroke onset predict treatment success? *Neurorehabil Neural Repair* 2007; 21:561-567.
19. Yu DT, Friedman AS, Rosenfeld EL. Electrical stimulation for treating chronic poststroke shoulder pain using a fully implanted microstimulator with internal battery. *Am J Phys Med Rehabil* 2010; 89:423-428.
20. Chae J, Wilson RD, Bennett ME, Lechman TE, Stager KW. Single lead percutaneous peripheral nerve stimulation for the treatment of hemiplegic shoulder pain: A case series. *Pain Pract* 2013; 13:59-67.
21. Nguyen VQ, Bock WC, Groves CC, et al. Fully implantable peripheral nerve stimulation for the treatment of hemiplegic shoulder pain: A case report. *Am J Phys Med Rehabil* 2015; 94:146-153.
22. Wilson RD, Gunzler DD, Bennett ME, Chae J. Peripheral nerve stimulation compared with usual care for pain relief of hemiplegic shoulder pain: A randomized controlled trial [published correction appears in *Am J Phys Med Rehabil*. 2016 Feb;95(2):e29]. *Am J Phys Med Rehabil* 2014; 93:17-28.
23. Wilson RD, Knutson JS, Bennett ME, Chae J. The effect of peripheral nerve stimulation on shoulder biomechanics: A randomized controlled trial in comparison to physical therapy. *Am J Phys Med Rehabil* 2017; 96:191-198.
24. Wilson RD, Bennett ME, Nguyen VQC, et al. Fully implantable peripheral nerve stimulation for hemiplegic shoulder pain: A multi-site case series with two-year follow-up. *Neuromodulation* 2018; 21:290-295.
25. Mehech D, Mejia M, Nemunaitis GA, Chae J, Wilson RD. Percutaneous peripheral nerve stimulation for treatment of shoulder pain after spinal cord injury: A case report. *J Spinal Cord Med* 2018; 41:119-124.
26. Wilson RD, Harris MA, Gunzler DD, Bennett ME, Chae J. Percutaneous peripheral nerve stimulation for chronic pain in subacromial impingement syndrome: A case series. *Neuromodulation* 2014; 17:771-776.
27. Elahi F, Reddy CG. Neuromodulation of the suprascapular nerve. *Pain Physician* 2014; 17:E769-E773.
28. Kurt E, van Eijk T, Henssen D, Arnts I, Steegers M. Neuromodulation of the suprascapular nerve. *Pain Physician* 2016; 19:E235-E239.
29. Ilfeld BM, Finneran JJ, Gabriel RA, et al. Ultrasound-guided percutaneous peripheral nerve stimulation: Neuromodulation of the suprascapular nerve and brachial plexus for postoperative analgesia following ambulatory rotator cuff repair. A proof-of-concept study. *Reg Anesth Pain Med* 2019; 44:310-318.
30. Mansfield JT, Desai MJ. Axillary peripheral nerve stimulation for painful end-stage primary osteoarthritis of the shoulder: A case report. *Neuromodulation* 2020; 23:878-880.
31. Mansfield JT, Desai MJ. Axillary peripheral nerve stimulation for chronic shoulder pain: A retrospective case series. *Neuromodulation* 2020; 23:812-818.
32. Manchikanti L, Hirsch JA, Cohen SP, et al. Assessment of methodologic quality of randomized trials of interventional techniques: Development of an interventional pain management specific instrument. *Pain Physician* 2014; 17:E263-E290.